

Strategies for the

Effective Management of Challenges Associated with Negative Pressure Wound Therapy



by Beth Hawkins Bradley RN, MN, CWON

Contents

Introduction.....	3
Determining When to Use Negative Pressure Wound Therapy	4
Patient Safety with Negative Pressure Wound Therapy	6
Dressing for Success: 9 Principles of Negative Pressure Wound Therapy Dressing Techniques.....	8
Preventing Maceration Associated With Negative Pressure Wound Therapy Dressings	11
Combating Wound Malodor Associated with Negative Pressure Wound Therapy	12
Creative Closure of Tunneling and Undermining Wounds.....	14
Combining Irrigation with Negative Pressure Wound Therapy	16
Is NPWT Enough? Three Products Commonly Combined with Negative Pressure	17
Negative Pressure Wound Therapy Patient Education Tool: Instruction Guide.....	20
References	22

Introduction

Over the past several years, Negative Pressure Wound Therapy (NPWT) has become a standard treatment for many wound types. Outcomes associated with the use of NPWT fall into two broad categories: Improved wound healing and improved wound care. Improved wound healing outcomes include two states: either a wound that has closed completely and requires no dressing, or a wound that has improved to the point that it can be closed surgically. Improved wound care outcomes reflect reduction in complications such as wound infection.¹ For large or complex wounds, the decrease in dressing change frequency and associated costs can offset the costs of using NPWT. Improved wound care may lead to improved wound healing, or it may be an outcome by itself. Therefore, when a clinician considers applying NPWT to a specific wound, several outcomes may be in mind.

There are general indications, contraindications, and precautions around the use of NPWT. Product manufacturers all have specific indications, contraindications and precautions listed in their FDA clearance letters. It is recommended that clinicians familiarize themselves with product specific usage guidelines. Generally, NPWT is indicated for acute and chronic wounds, pressure ulcers, dehisced surgical wounds, diabetic wounds, lower extremity venous wounds, trauma wounds, and burns. Contraindications for NPWT include: exposed vital organs, blood vessels and nerves; inadequately debrided wounds (generally, if the wound bed is obliterated with eschar or slough); untreated osteomyelitis or severe infection within the vicinity of the wound; presence of untreated coagulopathy; malignancy in the wound; allergy to any component required for the dressing. NPWT should be used with extreme caution when there is active bleeding, when the patient is on anticoagulants, when there is difficult wound hemostasis, or when placing the dressing in proximity to blood vessels.²

NPWT is also commonly used to treat wounds that do not fall within the stated indications. These include closed surgical incisions, enterocutaneous fistulas, and wounds in pediatric patients. Some manufacturers have obtained specific FDA clearance for devices whose primary purpose is incision management. Some traditional NPWT device manufacturers have an FDA cleared contraindication for unexplored enterocutaneous fistulas. While not specifically indicated for fistulas, clinicians use NPWT assuming that if the location and extent of the fistula has been confirmed, it is safe to use. Although most clinicians working with pediatric patients are familiar and comfortable with the use of NPWT in this population, the FDA has made it clear that this therapy is not indicated for use in neonates, infants, and children.³

Outcomes associated with the use of NPWT fall into two broad categories:



Improved wound healing

and



improved wound care.

Disclaimer: This paper will provide practical guidance around commonly encountered challenges in the application of NPWT. Areas of care including patient safety, wound bed preparation, wound closure techniques and odor management will be addressed. This e-book is not intended to serve as a substitute for clinical and operational guidance documents provided by NPWT manufacturers. It is critical that you familiarize yourself with guidelines for the device and dressings that you are using – there are many NPWT systems available for use. This guide is generally written for clinicians who use foam-based, powered systems.

Determining When to Use Negative Pressure Wound Therapy

During the early years of its use, NPWT was only used to treat large, difficult wounds. Now it is a standard treatment for a wide range of wounds. As a clinician interested in wound management, you are likely using this therapy frequently. But how knowledgeable are you about important aspects of NPWT? When is the best time to begin NPWT for a given wound? There is no protocol for answering this question. The answer must be derived from an understanding of the indications, contraindications, and precautions for NPWT. If a wound is indicated for NPWT, then the best time seems to be “anytime.”

How knowledgeable are you about important aspects of NPWT



The answer must be derived from an understanding of the indications, contraindications, and precautions.

TO SUMMARIZE:

Below are the generally accepted indications, contraindications and precautions for NPWT as outlined by Debra Nestch in Ruth Bryant’s text, *Acute and Chronic Wounds, 4th edition*.⁴ Some of these vary by manufacturer:

INDICATIONS: Acute, chronic, sub-acute, traumatic, and dehisced wounds, pressure ulcers, partial-thickness burns, flaps and grafts.

CONTRAINDICATIONS: Untreated osteomyelitis, malignancy in the wound, exposed organs, exposed blood vessels, non-enteric or unexplored fistulas, and necrotic tissue.

PRECAUTIONS: Active wound infections, potential for bleeding, treated osteomyelitis, surgical excision of malignancy, anticoagulant therapy, and poor patient compliance.

Many clinicians question waiting to use NPWT until all necrotic tissue is removed from the wound. It seems that the black open-cell reticulated (OCR) foam would help to provide mechanical debridement of necrotic tissue. The application of an enzymatic debridement ointment into the wound base prior to applying the NPWT dressing is widely believed to be helpful. However, understanding a few characteristics of black foam may change your mind about using negative pressure before the wound bed is free of necrotic tissue.

Black foam consists of open-cell, reticulated polyurethane. The pores that are visible in the foam help to not only move fluid away from the wound base, but also distribute negative pressure across the wound base and any existing dead space. The foam is not absorbent, it is hydrophobic. This function is a key property of effective NPWT. Therefore, it is important to keep the foam pores open.

Applying black foam over slough or other non-viable tissue can be counterproductive. The tissue has the potential to clog the foam pores. This prevents the movement of fluid and the distribution of negative pressure. Since bacterial load is higher in the presence of non-viable tissue, the wound fluid becomes a bacteria-laden “soup” with the potential for causing infection. Matrix metalloproteinase (MMP) levels will likely be increased, slowing wound granulation.

Enzymatic ointments can lead to the same result: clogged foam dressing pores. Additionally, most manufacturers recommend that the ointment remain in contact with the wound base for prolonged periods of time so that the cuff at the base of the slough can be broken. When the ointment is used with NPWT, it is likely moved away from the base very quickly, clogging the pores of the dressing and rendering its enzymatic properties ineffective.

The conclusion, then, is to delay negative pressure until the wound base is clean. The irrigation feature of some NPWT devices may make the therapy acceptable if scattered slough is present. Adding irrigation simultaneously with negative pressure will move a stream of fluid across the wound base, then moves it through the foam for a cleansing effect that keeps pores open. Bacterial load is likely decreased. The additional moisture may help with slough removal. In the absence of the ability to use irrigation, you may reconsider starting this therapy until after non-viable tissue is removed. If enzymatic ointments are employed, giving the necrotic tissue a vigorous scrub (as pain tolerance permits) can help with debridement.



Applying black foam over slough or other non-viable tissue can be counterproductive.

"The irrigation feature of some NPWT devices may make the therapy acceptable if scattered slough is present."

Patient Safety with Negative Pressure Wound Therapy

NPWT has been determined to be an acceptable and beneficial intervention for your patient. When deciding to use this valuable therapy to help your patients' wounds to heal, you must be aware that NPWT comes with risks. Legal professionals certainly understand this risk association. Refer back to the FDA Safety Alert issued in February 2011 in response to increased injuries among patients receiving NPWT.⁵ The FDA concluded that many of the injuries and deaths were related to insufficient observation of wound dressings and lack of patient teaching.

When I went to work for an NPWT company, I assumed responsibilities for education and support of our products. Parts of my duties include overseeing a 24-hour clinical support telephone line. I have been surprised and disturbed by the number of calls from patients who have been placed on NPWT, sent home from a facility or clinic, are seen by home care, but have received no training. In an effort to help you help your patients, below is a list of elements that should be included and documented for patients who are placed on NPWT.

- How to plug the device in and ensure that it is receiving power
- Take the power cord along when leaving home for any reason
- How many hours per day the device should be in use
- How to manage the device and dressing if showering is allowed
- How to turn the device on and off
- How to interpret alarms
- Canister change, safe handling and disposal
- How to detect bleeding, assessment of drainage in tubing and canister
- What a normally functioning dressing looks like
- How to detect and troubleshoot leaks (be sure that the patient has materials to patch with!)
- Action plan if a leak cannot be stopped; should the patient call his home health agency, go to an ED, or apply moist gauze dressings?
- Action plan for bleeding
- Emergency action plan
- How to reorder supplies when there is only one week's stock left
- How to contact clinical support for the device manufacturer

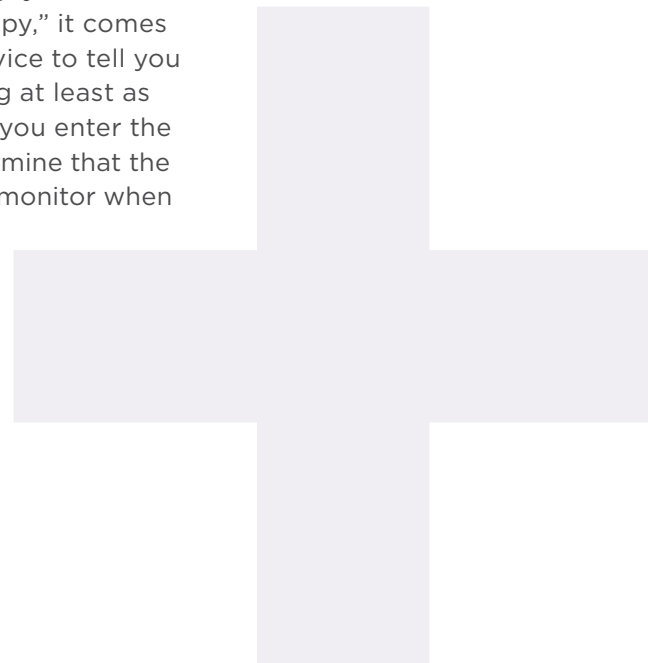


When deciding to use this valuable therapy to help your patients' wounds to heal, you must be aware that NPWT comes with risks.

Remember: giving your patient a fact sheet or verbal instructions is not enough. Have them quickly return demonstrate or repeat instructions back to you.

This list seems daunting, but you can accomplish this in a few minutes. As you are applying the dressing, talk to the patient about normal dressing appearance, detecting leaks and patching them. As you are setting up the NPWT device, have the patient or family member turn it on, place the canister, and plug it in. Discuss the other topics listed and reinforce with written patient guides. An efficient way to make sure that you cover both the instruction and documentation necessities is to include these elements in a form (see page 20), give one copy to the patient and keep a copy in the record.

If you are treating patients with NPWT in the inpatient setting, you are not off the hook. This therapy is not a “dress it and forget it therapy,” it comes with risks that require close monitoring. Never rely on the device to tell you if something is wrong with the dressing. Visualize the dressing at least as frequently as you visualize an IV site. Check the tubing when you enter the room for bloody drainage. Some facilities teach CANs to determine that the NPWT dressing is pulled down appropriately so that they can monitor when they do care tasks like turning and cleaning incontinence.



Dressing for Success: 9 Principles of Negative Pressure Wound Therapy Dressing Techniques

Dressing application, as noted above, provides an opportunity for us to educate our patients. And just how did you acquire your own knowledge and skills around the application of NPWT dressings? Most of us learned by observing another clinician doing dressing applications, or from a manufacturer's representative. We likely just imitated what they did, largely improvising. In my work over the past few years, I have been surprised to learn that many excellent clinicians have gaps in technical ability.

The information provided in this section is intended to review principles of NPWT dressing application to increase the accuracy of your techniques. These tips are distilled from principles that are typical of manufacturer guidelines. It is always recommended that you read and follow the manufacturer's guidelines for the product that you are using.

1. Cleanse the wound thoroughly prior to each dressing application. Evidence indicates that NPWT does reduce wound bacterial load, and cleansing the wound thoroughly will help in that effort. Additionally, cleansing will remove debris that can clog foam or feed bacteria. Irrigation across the wound bed is great, but remember to irrigate hidden dead spaces such as tunnels and undermined areas.

2. Remove devitalized tissue before starting NPWT. One of the contraindications for NPWT is undebrided eschar. Technically, NPWT is not contraindicated when slough is present. However, slough can impact the distribution of negative pressure across the wound bed as well as provide "food" for bacteria, so it is usually recommended to remove as much slough as possible before beginning NPWT. Some clinicians have developed the habit of using an enzymatic debriding ointment underneath the foam. This is a costly addition, and likely has minimal impact on the slough, as the enzymes need to be in contact with the base of the slough for sufficient time to break it down. When NPWT is applied, the ointment is pulled away from the base of the wound, and can clog the foam. You would be better off to spend a few extra days on vigorous mechanical cleansing before starting NPWT.

3. Use appropriate skin preparation techniques based on the needs of the individual. Some clinicians are hyperdiligent when it comes to skin protection under NPWT dressings. They will apply an elaborately prepared border of drape over skin coated with multiple layers of skin protectant. Only doing what is needed to protect the skin will save time and money. Many patients require only a light coating of protective barrier wipe. Also, there is no need to use the non-sting formulas on intact skin. Individualize periwound skin preparation based on the needs of the patient being treated.

The information provided in this section is intended to review principles of NPWT dressing application to increase the accuracy of your techniques.



4. Change your mind about the way that tunnels are filled. Tunnels need to be filled to prevent closure in the forward part of the tunnel and prevent seroma formation in the base of the tunnel. Instead of filling the entire tunnel, use the principle of placing a “wick” in the tunnel. This “wick” will extend the entire length of the tunnel, but allows the tunnel to collapse onto it, encouraging the tunnel to close faster. This wick may be made of gauze packing strip, non-adherent contact layer, or white foam. If white foam is used, make sure that the tensile strength is sufficient to prevent breakage upon removal. Always ensure that the tunnel filling material is long enough to be visible in the open wound base.

5. Don’t overfill undermined areas. The principle here is much the same as those for filling tunnels. Don’t “stuff” them, as the pressure from the foam against the wound can delay closure. If the foam you use is too thin, the tensile strength is reduced. You may need to wrap the thinned foam in a single layer of gauze or non-adherent contact layer in a sling like fashion. This ensures that you get out what you put in.

6. Fill the open wound with the right amount of foam. Compressing the foam, placing it into the wound, and then allowing it to expand places excessive pressure on the wound edges, which can delay wound contraction. The foam should be as exact a fit as is possible. This can be tricky with irregularly shaped wounds. It may be helpful to precut foam into a spiral, and then shape it into the wound.

7. Avoid thinning foam. Many clinicians assume that shallow wounds should be filled with thinned foam. Manufacturers construct foam of a certain thickness so that it will compress under pressure but still allow moisture to move through. When foam is thinned, foam can over collapse as negative pressure is achieved. This will prevent proper distribution of negative pressure and movement of fluids through foam. Thinning foam also increases the release of foam “crumbs” into the wound. It is fine for foam to extend higher than skin level even after it is compressed down. Make sure your bridge is wide enough. Just as thinned foam can over collapse, a narrow bridge can also over collapse. When constructing a bridge out of dressing foam, make sure that it is 1½” wide. This will prevent the foam from over collapsing.

8. Don’t stretch that drape! It is tempting to pull drape very tight when applying it over foam and onto skin so that wrinkles do not develop. Avoid the temptation to stretch the drape, since it can put traction on the skin and cause blisters.

Avoid thinning foam. Many clinicians assume that shallow wounds should be filled with thinned foam.

9. Use NPWT as a tool. Many clinicians apply NPWT dressings, turn the pump on, and never give a thought to using anything other than the device's default settings. Each time the dressing is changed, consider what pressure and mode are called for. For example, continuous mode is often called for during the initial days of NPWT, but moving into the intermittent mode after a week or two may speed granulation. After a time, returning to continuous may be useful. Think about the best pressure setting for the location and status of the wound being treated. For example, many clinicians use low, continuous pressures on newly dehisced abdominal wounds. Once the wound base is well granulated, they will increase pressures and begin intermittent mode therapy.


Another important note: Count and document the number of foam pieces that are placed and removed from the wound at each dressing change. It is not sufficient to write this data on the drape covering the wound. Place the count in your wound notes. Check to make sure the counts match at each dressing change. This protects both the patient and you!


Preventing Maceration Associated With Negative Pressure Wound Therapy Dressings

Even with extensive training on dressing application and refinement in techniques, patients may still present us with challenges. I am frequently asked for solutions to maceration of periwound skin in wounds being treated with NPWT. As a clinician practicing in the outpatient and home care settings, it was not unusual for patients to have to take a “holiday” from negative pressure. Treatment was often put on hold for several days to allow skin to recover. Putting negative pressure on hold not only caused a potential delay in forward progress in the wound, but it also created the need for increased dressing change visits for the home care patient. While maceration is reported in wounds located anywhere on the body, most clinicians who treat lower extremity wounds tell me that maceration is most severe in these wounds.

Recalling the impact of diabetes on the skin of the lower extremity may help clinicians understand why maceration associated with negative pressure is common. Neuropathic changes may include inappropriate sebaceous secretions, making the skin dry and unprotected against moisture. Inappropriate perspiration is also common. The increased skin moisture underneath the semi-permeable drape prevents evaporation and can contribute to moisture being retained on the skin. Skin impacted by diabetes has compromised ability to recover as maceration occurs,⁶ leading to the need for putting negative pressure on hold.

There are implications in dressing applications, as well as pressure and mode selections that can create or prevent maceration. As we examine these, you may find tips that can help you solve some of your clinical challenges.

 **SKIN PROTECTION:** Provide skin protection that best meets the needs of the individual patient. A protective barrier film wipe or spray is a good first step towards preventing maceration. These products apply a breathable layer of protection that allows the drape adhesive to stick to it. There are many brands of these products, each with unique characteristics. Get familiar with the characteristics of the product available to you on hand to make sure that it meets your needs. When applying any barrier film, begin applying at the edge of the wound and work outward to include all skin that will be covered by the drape. Allow the barrier film to dry before proceeding. Two coats may be helpful for fragile skin. In addition to applying skin barrier film, it may be necessary to apply a drape border around the wound edges. This may be done by overlapping 1” strips to frame the wound. Another option is to cut an opening in a piece of drape that is the exact shape of the wound before laying it onto the skin. Either way, drape may prevent maceration that results from moisture from the wound, but will likely not prevent maceration from inappropriate sweating.

 **TARGET PRESSURE SETTING:** When maceration occurs, many clinicians assume that it relates to wound fluid coming into contact with the periwound skin. They respond by increasing NPWT device pressures. Additionally, many clinicians use higher pressures in lower extremity wounds to begin with. In some cases, increasing pressures may actually

increase maceration. Black foam is hydrophobic, its job is to convey moisture through it. However, high pressures can cause compression and collapse of the foam cells, preventing moisture from being removed in the wound. If there seems to be excessive moisture in the wound and maceration to the surrounding skin, consider other strategies than increasing device pressures. In large wounds, you may find it helpful to apply two suction ports over different areas of the dressing, and Y connect them into the device. If you are bridging multiple large wounds, you may get better results pulling from directly over the wounds rather than bridging.

+ **MODE:** Most clinicians use NPWT in the default mode, which is continuous. The intermittent mode may be useful in preventing maceration in wounds that are small, or where higher pressures are used. The intermittent mode is different from manufacturer to manufacturer, but target pressure is held for a period of several minutes, alternated with a shorter period of time spent at atmospheric pressure. This cycle of pressure variation will allow the foam to relax, passing fluid through it and away from the wound.

+ **FOAM COMPRESSION IN SMALL WOUNDS:** It was mentioned earlier that lower extremity wounds frequently have maceration to the surrounding skin. Many of these wounds are small with depth. Consider the foam over-collapse concept associated with high pressure. Foam can also over collapse when it has low surface area. Pressure exerted over small surface area can close down the pores. Therefore, a wound with a small circumference but depth of even 1-2cm can over collapse and cause maceration. To prevent this, consider the “mushroom” or “button” dressing technique. Drape the periwound skin, fill the wound as usual, apply a full-thickness larger piece of foam over the wound, and finish the dressing as usual. This technique gives the foam larger surface area, preventing over-collapse.

Although maceration may not always be preventable, implementing these strategies may help to reduce its impact. Always assess your patient carefully prior to beginning NPWT, and consider how the skin should be protected, as well as which device settings will be most beneficial.

Wound beds should be properly prepared prior to beginning NPWT.

Combating Wound Malodor Associated with Negative Pressure Wound Therapy

Any clinician who works with NPWT dressings will report that a significant number of wounds will develop a malodor, commonly referred to as a “VAC stink.” In response to malodor, clinicians often opt to give the wound a NPWT holiday, which, as noted previously, can delay wound closure. Let’s look at factors that contribute to malodor, and interventions that might reduce it.

Malodor is not only associated with NPWT dressings, but it also occurs with other occlusive dressings. Several reasons for malodor have been theorized, but increased bacterial load is generally thought of as the primary factor leading to malodor.⁷

As explained earlier, wound beds should be properly prepared prior to beginning NPWT. Slough provides a medium for increased bacterial load in a wound. Byproducts of bacterial metabolism include ammonia and sulfur compounds. So by removing non-viable tissue prior to beginning NPWT, the risk of malodor can be reduced.

There have been questions raised about the use of Active *Leptospermum* Honey (ALH) in conjunction with NPWT to reduce malodor. ALH has properties that may impact bacterial load, thus reducing odor. Edna F. Ganacias-Acuna, MD explains these possible mechanisms for ALH's effectiveness in reducing malodor in a published case study.⁸ The glucose component of honey increases osmotic pressure in the wound, attracting fluid into the wound. This fluid helps to soften non-viable tissue to speed autolytic debridement. Less non-viable tissue means fewer bacteria in the wound and less odor. Bacteria remaining in the wound prefer to metabolize glucose rather than the body's cellular components. The byproduct of glucose metabolism is lactic acid, which does not have the odor associated with ammonia and sulfur compounds produced by metabolism of other proteins.⁹ Honey produces hydrogen peroxide, giving it antimicrobial properties. The use of honey, however, increases the cost of dressings, and may impact the distribution of negative pressure across the wound.

We are, therefore, back to the issue of wound cleansing. The importance of thoroughly flushing and cleansing the wound base and all undermining/tunnels at each dressing change cannot be over-emphasized. In working with clinicians around the country, I find that little effort is given to this important part of wound management. Frequently I notice that the NPWT dressing is removed, the wound is wiped with a moist gauze, and the next NPWT dressing is applied. The impact of this manner of cleansing is questionable.

Irrigation or instillation delivered in conjunction with NPWT is an intervention with documented results in reducing bacterial load in wounds.¹⁰ Some NPWT manufacturers offer options for delivering irrigants either simultaneous to negative pressure, or during an off cycle of the therapy. Some clinicians effect irrigation simultaneously by tunneling an IV tubing into the dressing and delivering fluid in a slow steady stream. Dr. David Armstrong coined the word "chemovac" to define the delivery of various antibiotics and antimicrobials along with NPWT.¹¹ Delivering irrigation simultaneous to NPWT not only moves bacteria, but will soften slough to aid in its removal, cleanse debris, and cleanse the foam.

Topical silver used in conjunction with NPWT is a common practice because of its antimicrobial properties. There are many forms of silver available for use with NPWT including silver foam, wound contact layers, powders, alginates and hydrofibers. The costs and properties of each form should be considered before applying these products in order to achieve maximum antimicrobial benefit without jeopardizing delivery of NPWT. Some products may cause foam clogging, alginates being one example.

Since bacteria are a key causative factor in the development of malodor, reducing bacterial load is an important part of the NPWT plan of care. As with any aspect of local care, a protocol approach will not be as effective as considering each wound individually and using the adjuncts best suited for it.



The importance of thoroughly flushing and cleansing the wound base and all undermining/tunnels at each dressing change cannot be over-emphasized.

Creative Closure of Tunneling and Undermining Wounds

Wounds treated with NPWT are not often straightforward and present us with many challenges. They occur in interesting places, have anything from slough to hardware visible in the bases, and have nooks and crannies that are not visible to the clinicians peering into the wound. A gentle probe is necessary during wound assessment to identify tunnels and undermined areas. I prefer to gently probe first with my gloved finger (I have small hands) because I can identify hidden structures and other oddities. Then I will use a swab to measure how far the tunnel or undermining extends. Once hidden dead spaces have been identified, clinicians can select the best strategy to bring them to closure. Herein are several techniques employed by clinicians to close undermined and tunneled areas.

White foam is a preferred option in closing tunneling and undermined wounds in NPWT. Some foam-based NPWT manufacturers offer white foam, but not all. White foam is hydrophilic. It is intended to hold moisture next to structures like tendon, bone and hardware. The extent to which wound fluid is able to move through hydrophilic foams depends on the material that the foam consists of. Some foams are made of polyvinyl alcohol (PVA) material. This foam must remain moist or it will become quite hard, and has limited ability to move moisture through it. Review clinical guidelines, as typically it is recommended that pressures be increased with PVA foam. White foam constructed of polyurethane (PUA) is also available from some manufacturers. This is soft even when dry, and does not require pressures be increased to move fluid.

When using white foam to fill tunnels or undermined wound areas, make sure that you do not overfill the dead space. Although you want to fill to within 1cm of the back of the tunnel or undermined area, it is preferable to allow the volume to collapse around the foam to speed granulation. Make sure that a sufficient amount of white foam protrudes from the opening so that it is easily identified at the dressing change.

"Make sure that a sufficient amount of white foam protrudes from the opening so that it is easily identified at the dressing change."

While white foam is useful, it is not always available. Medicare and other third party payers do not cover it, so clinicians in the outpatient and home care settings have to find alternatives when there is hidden dead space to fill in a wound. Two materials that are readily available in most settings include gauze

packing strips and wound non-contact layers. These materials have an advantage of allowing tunnels to collapse around it easily, but prevent seroma formation. However, it is difficult to use these materials for large undermined areas. While black foam might be preferable, the risk of breakage is real. A great way to use black foam safely in undermined areas or long wound tunnels is to roll it in a single layer of gauze or wound non-contact material. This technique gives insurance that all of the black foam will be removed while minimally impacting its ability to move moisture.

Some clinicians choose not to fill tunnels and undermined areas at all; rather they bolster the hidden dead space from above to promote wound closure. Below are the steps that are usually followed when bolstering undermined areas or tunnels.

- 1.** Carefully assess the area to be certain how far it extends.
- 2.** Drape the skin overlying the dead space.
- 3.** Apply a full-thickness piece of foam on the draped skin overlying the entire dead space. Make sure the foam connects onto foam used to fill the wound. Drape the foam bolster with the rest of the wound, and complete the NPWT dressing application as usual.
- 4.** As the dressing pulls down and achieves target pressure, gently press over the bolstered area to ensure that the wound underlying the bolster has sealed.

The risk of this technique includes seroma or abscess formation, so the prescribing provider should always approve of this technique being employed.

Hidden dead spaces must always be thoroughly cleansed at each dressing change to remove debris and reduce bioburden. Since irrigation of the areas may be challenging, a syringe can be a useful tool to irrigate. Closure of undermined and tunneled areas is essential in achieving wound healing success.

Hidden dead spaces must always be thoroughly cleansed at each dressing change.

Combining Irrigation with Negative Pressure Wound Therapy

Increased attention has been focused on wound bioburden and its impact on wound progress. Product manufacturers have responded by developing antimicrobials in many forms. Antimicrobial solutions used as wound soaks or wound cleansers have become popular. As mentioned in the previous section, clinicians combine antimicrobial products with NPWT dressings in an off label use to try to speed wound progress by decreasing bacterial load. Combining wound irrigation with negative pressure is becoming increasingly popular. Although two product manufacturers have offered this feature for years, the increased interest in decreasing bioburden has driven the utilization of the modality. This section will describe the two methods of irrigation delivery, and discuss the benefits of adding irrigation to NPWT.

When combined with negative pressure, irrigation may be delivered either simultaneously or intermittently. With the simultaneous method, a stream of fluid continuously enters the negative pressure dressing through an irrigation port. Capillary and stochastic forces draw the fluid down through the foam, across the wound base (including undermining and tunnels) and then up and out through the suction port. Thus there is a continuous movement of fluid through the foam and across the wound bed. Simultaneous irrigation is offered by one manufacturer, but may also be initiated by tunneling a catheter into the negative pressure dressing material. Irrigant is maintained within the wound area, therefore there is infrequent periwound maceration. Set up is simple, and the clinician only has to decide the best irrigation flow rate for the wound.

Intermittent irrigation is just that, a cyclical introduction of irrigant into the wound dressing. The biggest difference is that negative pressure cycles off during the instillation of irrigant. Intermittent delivery of irrigation requires that the clinician determine the volume of fluid to be delivered, how long the fluid will dwell in the wound before the device turns on, and how frequently the cycle will be repeated. Intermittent irrigation may have increased incidences of periwound maceration, and is a little more complicated to set up.

The obvious benefit of irrigation with NPWT would appear to be wound cleansing. The effects of cleansing the foam dressings may be equally important. When foam is removed from the wound at dressing change time, you can't help but notice that it often has a slimy appearance. During the few days that foam is in place, components of exudate that include fibrin and "reconstruction" debris adhere to the foam. Thick exudate may become trapped in areas of the foam. The net effect is that foam pores may become partially clogged, causing impaired distribution of negative pressure. When irrigation is combined with negative pressure, one of the benefits is foam cleansing. Clean foam provides for optimum distribution of negative pressure, and potentially faster granulation. More study needs to be done to document this benefit.

Besides cleansing foam, irrigation with NPWT impacts bacterial load in wounds. If bioburden is decreased, then chronic inflammatory states and biochemicals associated with wound non-progress are decreased. Several studies exist that demonstrate decreased bioburden with both types of NPWT irrigation delivery.

"The obvious benefit of irrigation with NPWT would appear to be wound cleansing. The effects of cleansing the foam dressings may be equally important."

One of the most frequently asked questions that I receive related to irrigation is "Which solution should I irrigate with?" In my clinical practice, I was a strong proponent of antimicrobial solutions, Dakin's Solution being my favorite. When I began using irrigation with NPWT, I frequently used it as my irrigant of choice. Besides being a broad spectrum antimicrobial, it has properties that improve breakdown of slough. A recent study grabbed my attention because it has the potential to change my preference. In a study looking at the impact of simultaneous irrigation on infected wounds (acute wounds in pigs), some interesting results were noted.¹² As expected, NPWT alone decreased bioburden over traditional dressings. When irrigation was added, bioburden decreased even further. Here's what really grabbed my attention: there was no significant difference in bacterial load between wounds irrigated with saline and wounds irrigated with Prontosan (a commercial antimicrobial solution). Therefore, using saline combined with NPWT, which is inarguably safe and inexpensive, may be as effective as antibiotic and antimicrobial solutions.

Irrigation with NPWT will be an area of much study over the next few years, but it has the potential even now to speed wound progress and therefore reduce time and money spent on wound care. You should at least consider it on your more complicated wounds, and wounds that are not progressing as rapidly as you expect. It certainly provides a solution for clinicians who believe that the wounds that they treat are not being properly cleansed.

Is NPWT Enough? Three Products Commonly Combined with Negative Pressure

Finding the key to unlocking a non-healing chronic wound keeps us awake at night. Though we have, as bedside clinicians, learned much about the physiology and biochemistry of chronic wounds over the past decade, wound healing is not an exact science. NPWT has become standard care for certain chronic wounds. Sometimes, however, wounds treated with this therapy do not progress as readily as we think that they should. This has led us to consider combining other wound care products with NPWT, which have all been mentioned earlier in this guide. We will examine the rationale for using several products in combination with negative pressure.

Enzymatic debriding ointments are frequently combined with negative pressure to hasten the removal of necrotic tissue even as NPWT is applied.



Though we have...learned much about the physiology and biochemistry of chronic wounds over the past decade, wound healing is not an exact science.


When clinicians understand the labeling for both products, they can make an informed decision about this combination. First of all, NPWT is contraindicated in wounds with unbridged eschar. When eschar is debrided, slough frequently remains in the wound base. Remember that slough that obliterates the wound base prevents NPWT from being effective because of two factors – slough clogs foam pores which prevents the distribution of negative pressure and reduces the removal of exudate, and slough prevents contact of the foam in the wound base which prevents microstrain and granulation.

Clinicians may apply enzymatic debridement agents in conjunction with NPWT to hasten the removal of slough. Labeling for these products indicates that the ointment must be in contact with the base of the slough for a period of time in order for the product to be effective in breaking down necrotic collagen tissue. Therefore, when an enzymatic debridement agent is applied to a wound and NPWT is begun immediately, the impact of the debridement may be greatly reduced. Further, the ointment may clog foam pores, causing the same impact that the slough does. In considering expense, it may be more cost-effective to aggressively remove slough before applying NPWT. If NPWT must be applied, consider using a system that allows for irrigation. The streaming of fluid across the wound will likely remove slough effectively, and will keep foam pores open.

Silver is another product that is frequently combined with NPWT. There is no question of the benefit of silver in reducing wound bioburden.¹³ Clinicians should take care to understand the properties and application considerations for the silver product that is used. Most often a silver wound contact layer is chosen to be used in conjunction with NPWT. The benefit of using silver in this form is that the silver is in contact with the wound base. Wound fluid is allowed to move through the mesh freely. Microstrain may be slightly reduced, since the wound contact layer prevents foam from coming in direct contact with the wound base. Using silver wound contact layers is usually less expensive than silver impregnated foam. When using silver in combination with NPWT, remember to use it for a specific length of time and for a specific purpose. Finally, silver can render enzymatic debridement agents inactive, so combining those products is contraindicated. Avoid using silver impregnated alginates or hydrofibers, as these products will clog foam. If irrigation is used in conjunction with NPWT, silver will likely not be needed.

Honey combined with NPWT has become an intriguing idea to some clinicians. Honey has antibiotic/antimicrobial properties, and increases the osmolarity of the wound environment. These features have led clinicians to combine honey with NPWT to reduce odor associated with the use of NPWT in certain wounds. The increased exudate associated with increased osmolarity may assist with slough removal. Medical honey products can add significant cost to NPWT dressings. Some formulations may impact the effectiveness of NPWT by clogging foam pores and reducing foam interface with the wound base. There is a honey-impregnated wound contact layer available that may reduce the negative impact of a paste or alginate combination honey product. If an NPWT system with irrigation is available, the need for adding honey will likely be eliminated.

There are many other products, therapies and techniques that clinicians can combine with NPWT to enhance outcomes and decrease healing times. It is



There is a honey-impregnated wound contact layer available that may reduce the negative impact of a paste or alginate combination honey product.

important to understand product indications and application guidelines to make sure that their combination with NPWT will be beneficial. The irrigation feature that is available with certain NPWT systems may be very effective in eliminating the need for product combinations, so become familiar with these functions. Clinicians should have a strong working knowledge of the devices, dressings and products they are using to deliver NPWT to their patients. Patients should demonstrate an understanding of their role in the treatment process and the dressings and devices used; this, too, is the responsibility of the clinician providing treatment.

Wounds present us with many challenges in achieving healing outcomes. By assessing the wound and treatment options, in addition to considering other products that might aid in the delivery of NPWT, an effective strategy may be employed to ultimately improve wound healing and improve wound care.

About the Author

Beth Hawkins Bradley, RN, MN, CWON has been certified in the specialty of Wound, Ostomy, Continence nursing since 1990. She has been the sole proprietor of Care On Call, which provides consultation and education for clinicians and patients. In 2010, Ms. Bradley joined Innovative Therapies, Inc. as the Director of Clinical Affairs and currently holds the position of VP Clinical Education.

Disclosure:

Financial: Employed by Innovative Therapies, Inc.

Negative Pressure Wound Therapy Patient Education Tool: Instruction Guide

This guide is intended to assist home care and outpatient clinicians to provide instruction and documentation related to the use of the prescribed negative pressure wound therapy (NPWT) device for home use. Use this guide in the home/outpatient setting as you instruct your patients. Please check the appropriate box as you instruct your patient, step-by-step, through the operation of the NPWT device. Please have your patient sign the tool at the end of the session, and include the form in the patient's medical record. Provide the patient with a copy of the guide for reference.

Device Make/Model: _____

Elements to instruct/demonstrate Reinstruction during consecutive home visits may be needed	Verbal recall	Return demonstration	Identify phone number or button
--	---------------	----------------------	---------------------------------

DEVICE BASICS - Instruct and obtain verbal/return demonstration of the following:

Turning device on and off	<input type="checkbox"/>	<input type="checkbox"/>	<input type="checkbox"/>
Identify low battery alarm	<input type="checkbox"/>	<input type="checkbox"/>	<input type="checkbox"/>
Plug power cord into device and power outlet	<input type="checkbox"/>	<input type="checkbox"/>	<input type="checkbox"/>
Identify canister full alarm	<input type="checkbox"/>	<input type="checkbox"/>	<input type="checkbox"/>
Demonstrate canister change	<input type="checkbox"/>	<input type="checkbox"/>	<input type="checkbox"/>
Identify low pressure/leak alarm	<input type="checkbox"/>	<input type="checkbox"/>	<input type="checkbox"/>
Demonstrate verification that tubing clamp is open	<input type="checkbox"/>	<input type="checkbox"/>	<input type="checkbox"/>

HOW TO RECOGNIZE EXCESSIVE BLEEDING:

Definition of excessive bleeding (list parameters given to patient below)

ACTION PLAN FOR BLEEDING: Includes but is not limited to turning device off, apply pressure over dressing, call emergency contact (MD, home care agency, 911) (List parameters given to patient below, verifying correct phone numbers)

Identify both prescription and OTC medications that have anticoagulants effects that the patient is taking with instructions for their use (List applicable medications below)

ADDITIONAL INSTRUCTIONS: Identify

Elements to instruct/demonstrate Reinstruction during consecutive home visits may be needed	Verbal recall	Return demonstration	Identify phone number or button
The pump will be very quiet when the pressure in the dressing is stable at the set level	<input type="checkbox"/>	<input type="checkbox"/>	<input type="checkbox"/>
Fluid in the suction tubing may not move when the pressure in the wound is stable. This is normal and no action is needed	<input type="checkbox"/>	<input type="checkbox"/>	<input type="checkbox"/>

ADDITIONAL INSTRUCTIONS: (please list)

How to recognize an infection and/or if wound is worsening:

Signs and symptoms of wound infection including: Increased pain, increased wound drainage, change in drainage color, odor that persists after wound cleansing, periwound inflammation, negative change in wound base appearance or depth	<input type="checkbox"/>	<input type="checkbox"/>	<input type="checkbox"/>
--	--------------------------	--------------------------	--------------------------

Action plan for excessive pain in or near the wound: Instruction should include but may not be limited to:

Call appropriate provider	<input type="checkbox"/>	<input type="checkbox"/>	<input type="checkbox"/>
---------------------------	--------------------------	--------------------------	--------------------------

Other instructions: (please list)

Review Troubleshooting Section in Patient Guide:

Blockage or Occlusion alarm if applicable	<input type="checkbox"/>	<input type="checkbox"/>	<input type="checkbox"/>
---	--------------------------	--------------------------	--------------------------

Low Pressure/Leak Alarm Sounds: May Include But Not Limited To Options Below:

Use hands to press over the suction port and drape to attempt to seal leak that might have occurred	<input type="checkbox"/>	<input type="checkbox"/>	<input type="checkbox"/>
Place extra drape over area where leak is identified	<input type="checkbox"/>	<input type="checkbox"/>	<input type="checkbox"/>

If unable to get a seal, implement the following procedures:

Turn device off, remove the drape and foam, apply wet to damp gauze dressing to wound	<input type="checkbox"/>	<input type="checkbox"/>	<input type="checkbox"/>
Notify home care agency or wound clinic staff	<input type="checkbox"/>	<input type="checkbox"/>	<input type="checkbox"/>

Clinician's name _____ Signature _____ Date _____

Clinician's name _____ Signature _____ Date _____

Patient's name _____ Signature _____ Date _____

References

1. Guidance for industry: chronic cutaneous ulcer and burn wounds — developing products for treatment. U.S. Food and Drug Administration, Center for Drug Evaluation and Research Website. Published June, 2006. Available at:<http://www.fda.gov/downloads/Drugs/GuidanceComplianceRegulatoryInformation/Guidances/ucm071324.pdf>. Accessed July 30, 2013.
2. Technology assessment on negative pressure wound therapy devices. Agency for Healthcare Research and Quality Website. Published November 2009. Available at: <http://www.ahrq.gov/research/findings/ta/negative-pressure-wound-therapy/background.html>. Accessed July 30, 2013.
3. FDA Safety Communication: UPDATE on Serious Complications Associated with Negative Pressure Wound Therapy Systems. U.S. Food and Drug Administration Website. Published February 24, 2011. Available at: <http://www.fda.gov/MedicalDevices/Safety/AlertsandNotices/ucm244211.htm>. Accessed July 30, 2013.
4. Netsch D. Negative Pressure Wound Therapy. In: Bryant R. *Acute and Chronic Wounds: Current Management Concepts*. 4th ed., St. Louis, Mo: Mosby Elsevier; 2012:337-344.
5. FDA Safety Alert. Negative Pressure Wound Therapy (NPWT) systems - Preliminary Public Health Notification. U.S. Food and Drug Administration Website. Published February 24, 2011. Available at: <http://www.fda.gov/Safety/MedWatch/SafetyInformation/SafetyAlertsforHumanMedicalProducts/ucm190704.htm>. Accessed July 30, 2013.
6. Rodgers A, Watret L. Maceration and its effect on periwound margins. *Diabetic Foot* 2003; 6(3 Suppl): S2-S5.
7. Kumar, P. Limited access dressings. *Wounds*. 2008;20(2):49-59.
8. Ganacias-Acuna E. Making Progress with Stalled Wounds: Active *leptospermum* honey and negative pressure wound therapy for non-healing post-surgical wounds. *OW-M*. March 2012;10-12.
9. Stotts N, Bryant R. *Acute and Chronic Wounds: Current Management Concepts*. 4th ed., St. Louis, Mo: Mosby Elsevier; 2012:272.
10. Gabriel A, Shores J, Heinrich C, et al. Negative pressure wound therapy with instillation: a pilot study describing a new method for treating infected wounds. *Int Wound J*. 2008; 5(3):399-413.
11. Giovinco NA, Bui TD, Fisher T, Mills JL, Armstrong DG. Wound chemotherapy by the use of negative pressure wound therapy and infusion. *Eplasty*. 2010;10:e9.
12. Davis K, Bills J, Barker J, Kim P, Lavery L. Simultaneous irrigation and negative pressure wound therapy enhances wound healing and reduces wound bioburden in a porcine model. *Wound Repair Regen*. 2013 Oct 17. Vol. 21(6):869-875.
13. International consensus. Appropriate use of silver dressings in wounds. An expert working group consensus. London: Wounds International, 2012. Available at: http://www.wound-international.com/pdf/content_10381.pdf. Accessed March 20, 2014.

WOUND SOURCE

2014 Board Members

CLINICAL EDITOR:

Catherine T. Milne, APRN, MSN, BC-ANP, CWOCN-AP
Connecticut Clinical Nursing Associates, LLC, Bristol, CT

FOUNDING EDITOR:

Glenda J. Motta, RN, BSN, MPH, ET
GM Associates, Inc., Loveland, CO

EDITORIAL ADVISORY BOARD:

Cordell "Corky" Atkins, PT, DPT, CWS, CDE, CPed
Intermountain Diabetic Foot Clinic, Murray, UT

Elizabeth A. Ayello PhD, RN, ACNS-BC, CWON, MAPWCA, FAAN
Ayello, Harris & Associates-President, Copake, NY

Sharon Baranoski, MSN, RN, CWCN, APN-CCNS, FAAN, MAPWCA
Wound Care Dynamics, Shorewood, IL

Jacalyn A. Brace, PhD, RN-BC, CWOCN, APRN-BC
Widener University School of Nursing, Chester, PA

Paula Erwin-Toth, MSN, RN, CWOCN, CNS, FAAN
PETprojects: Wound, Ostomy and Continence Care, Education and Advocacy, Deerfield, OH

Chuck Gokoo, MD, CWS
American Medical Technologies, American Medical Technologies, Lewisville, TX

Allen Holloway, MD
Maricopa Medical Center, Dept. of Surgery, Phoenix, AZ

Martha Kelso, RN, HBOT
Mobile Wound Solutions, Independence, MO

Diane Krasner, PhD, RN, CWCN, CWS, MAPWCA, FAAN
Wound & Skin Care Consultant, York, PA

James McGuire, DPM, FAPWCA, PT, CPed
School of Podiatric Medicine-Temple University, Philadelphia, PA

Michael S. Miller, DO, FACOS, FAPWCA, WCC
The Miller Care Group, Indianapolis, IN
The Miller Care Group (Indy Lymphedema, Indy Wound Care, Indy Nutrition), Indianapolis, IN

Marcia Nusgart, R.Ph.
Coalition of Wound Care Manufacturers, Alliance of Wound Care Stakeholders, Bethesda, MD

Mary Ellen Posthauer, RDN, CD, LD
MEP Healthcare Dietary Services, Evansville, IN

Donna Sardina, RN, MHA, WCC, CWCMS, DWC
Wound Care Education Institute, Lake Geneva, WI

Pamela Scarborough, PT, DPT, MS, CDE, CWS, CEEAA
American Medical Technologies, Wimberley, TX

Kathleen D. Schaum, MS
Kathleen D. Schaum & Associates, Inc., Lake Worth, FL

Thomas E. Serena, MD, FACS, FACHM, MAPWCA
SerenaGroup, Cambridge, MA

Aletha W. Tippet, MD
Advanced Wound Team, Cincinnati, OH

Chenel Trevellini, RN, MSN, CWOCN
St. Francis Hospital, Roslyn, NY

Toni Turner, RCP, CHT, CWS
The Woodlands, TX

Kevin Y. Woo, PhD, RN, FAPWCA
Queen's University, Kingston, Ontario

WoundSource Team

BUSINESS STAFF

Publisher/President | Jeanne Cunningham
jeanne@kestrelhealthinfo.com

Vice President | Brian Duerr
brian.duerr@kestrelhealthinfo.com

Print/Online Production Manager | Christiana Bedard
christiana@kestrelhealthinfo.com

EDITORIAL STAFF

Managing Editor | Miranda Henry

Copy Editor | Victoria Beliveau

PRODUCTION STAFF

Production Associate | Arnis Gubins

Graphic Design | Amanda Coyle

Web Programming and Design | Dave Myburgh

HOW TO REACH US

Corporate Office:
P.O. Box 189 - 206 Commerce St., Hinesburg, VT 05461

Phone: (802) 482-4000 - **Fax:** (802) 329-2077

E-mail: info@kestrelhealthinfo.com

Website: www.kestrelhealthinfo.com, www.woundsource.com

Editorial inquiries: editorial@kestrelhealthinfo.com

Advertising inquiries: sales@kestrelhealthinfo.com

TERMS OF USE

All rights reserved. No part of this report may be reproduced or transmitted in any form or by any means, electronic or mechanical, including photocopying, recording, faxing, emailing, posting online or by any information storage and retrieval system, without written permission from the Publisher. All trademarks and brands referred to herein are the property of their respective owners.

LEGAL NOTICES

The contents of this publication are for informational purposes only. While all attempts have been made to verify information provided in this publication, neither the author nor the publisher assumes any responsibility for error, omissions or contrary interpretations of the subject matter contained herein. The purchaser or reader of this publication assumes responsibility for the use of these materials and information. Adherence to all applicable laws and regulations, both referral and state and local, governing professional licensing, business practices, advertising and all other aspects of doing business in the United States or any other jurisdiction, is the sole responsibility of the purchaser or reader. The author and publisher assume no responsibility or liability whatsoever on the behalf of any purchaser or reader of these materials. Any perceived slights of specific people or organizations are unintentional.

For more free White Papers visit www.woundsource.com

FOLLOW US ON TWITTER AND FACEBOOK:

 @woundsource |  Find us on Facebook | www.facebook.com/woundsource